

Expression of the Epstein-Barr Virus Latent Membrane Protein in Nasopharyngeal Carcinoma Biopsy Specimens

JAMES P. STEWART, PHD,* AND JOHN R. ARRAND, PHD

It has been known for some time that the Epstein-Barr virus (EBV) is associated with nasopharyngeal carcinoma (NPC). The tumor cells are known to harbor EBV in a latent state. Latently-infected B cells that have become growth transformed by EBV in vitro express some 10 antigens, two of which (Epstein-Barr nuclear antigen 2 [EBNA2] and the latent membrane protein [LMP]) are associated with cellular transformation. We evaluated the expression of these two EBV antigens in NPC by probing tissue sections with monoclonal antibodies. We found that EBNA2 was not expressed and that LMP was expressed in seven of nine biopsy specimens. It is therefore postulated that either there are subsets of NPC or that LMP may be involved only in certain stages of tumor formation. *HUM PATHOL* 24:239-242. Copyright © 1993 by W.B. Saunders Company

The Epstein-Barr virus (EBV) is a member of the herpesvirus family and is ubiquitous in all human populations. Primary infection with EBV usually occurs at an early age, is clinically inapparent, and results in life-long virus persistence.¹ However, if infection with EBV is delayed, the self-limiting lymphoproliferative disorder known as infectious mononucleosis often ensues. The presence of EBV also has been associated with several human malignancies. The virus displays a tropism for B lymphocytes and epithelial cells^{2,3} and, in line with these tropisms, EBV has been associated with several tumors, including polyclonal B lymphoproliferations in immunosuppressed individuals,⁴ Burkitt's lymphoma,⁵ and nasopharyngeal carcinoma (NPC).

Nasopharyngeal carcinoma is an epithelial cell tumor arising in the back of the postnasal space and is most prevalent in the southern Chinese, in whom it has an incidence of up to 25 per 100,000 individuals per year.⁶ Epstein-Barr virus is associated mainly with the poorly differentiated or undifferentiated forms of the tumor, 100% of which have been shown to harbor the virus genome.^{7,8} It has been shown subsequently that virus DNA is associated with the malignant epithelial cells in biopsy specimens and not with the lymphocytes that tend to infiltrate these tumors.⁹

Resting B lymphocytes have the capacity to be immortalized by EBV in vitro and, as such, harbor the virus in a "latent" state, in which it expresses only a

restricted set of genes. When the first studies of EBV gene expression in NPC were performed, the only EBV protein known to be expressed in latently infected B cells was the Epstein-Barr nuclear antigen (EBNA). This antigen had been described by using EBV-seropositive human sera in an anti-complement immunofluorescence assay and, as such, was a poorly characterized phenomenon.¹ Thus, initially, in a way analogous to the case of in vitro immortalized B cells, it was found that NPC biopsy cells harbored EBV in a latent state and that the only EBV antigen expressed by them was "EBNA."^{10,11} More recently, it has been discovered that EBNA consists of a number of individual latent proteins identified as EBNA1, 2, 3a, 3b, 3c, and leader protein (for review, see ref 12). In addition to six nuclear proteins, three latent cycle membrane proteins termed "latent membrane protein" (LMP¹³), "terminal protein 1," and "terminal protein 2"¹⁴ also have been found. Little is known about the function of these proteins; however, both EBNA2 and LMP have been associated with aspects of the cellular transformation process.¹⁵⁻²⁰ Since the dissection of EBV latent gene expression, only two studies of EBV antigen expression in NPC biopsy specimens have been performed. These showed that the only antigens present were EBNA1 and LMP, the former being present in 100% and the latter being present in only 70% of biopsy specimens.^{21,22} Both studies, however, used Western blot analysis which, although sensitive, gives no information on expression at the single cell level. It is possible, therefore, that the LMP observed in these studies was expressed by lymphocytes that infiltrate NPC biopsy specimens²³ and not by the tumor cells.

In this study we used monoclonal antisera to reassess at a single-cell level whether EBV proteins that are involved in cellular transformation (that is, EBNA2 and LMP) were expressed in NPC biopsy specimens. We found that LMP, but not EBNA2, was detected in the majority of the biopsy specimens and was expressed in the epithelial (tumor) cells present in the specimens.

MATERIALS AND METHODS

Tissue Sections

Nine tumor biopsy specimens that had been originally histologically diagnosed as undifferentiated NPCs were obtained from Jin-Quan Jiang, Shanghai Cancer Center (Shanghai, People's Republic of China) as snap-frozen tissue. Serial sections of 7 μ m thickness were cut from each specimen, dried onto sialane-treated glass microscope slides, and fixed in acetone for 3 minutes.

From the Department of Molecular Biology, Paterson Institute for Cancer Research, Christie CRC Cancer Centre, Manchester, UK. Accepted for publication July 9, 1992.

* Present address: Department of Virology, St Jude Children's Research Hospital, Memphis, TN.

Supported by the Cancer Research Campaign (UK).

Key words: Epstein-Barr virus, nasopharyngeal carcinoma, latent membrane protein, Epstein-Barr nuclear antigen 2.

Address correspondence and reprint requests to John R. Arrand, PhD, Department of Molecular Biology, Paterson Institute for Cancer Research, Christie CRC Cancer Centre, Manchester, M20 9BX, UK.

Copyright © 1993 by W.B. Saunders Company
0046-8177/93/2403-0003\$5.00/0

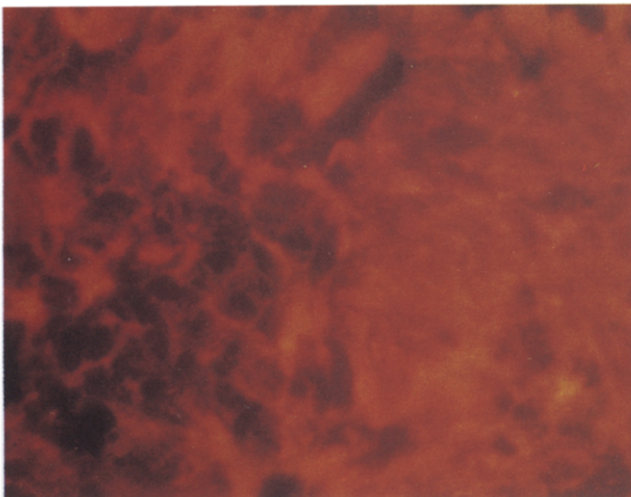
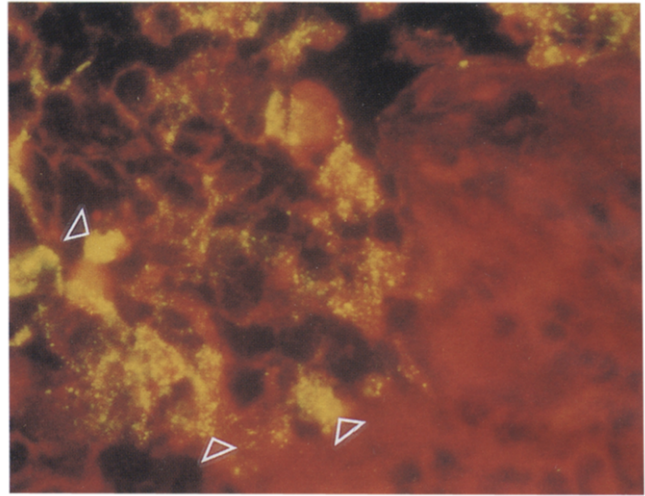
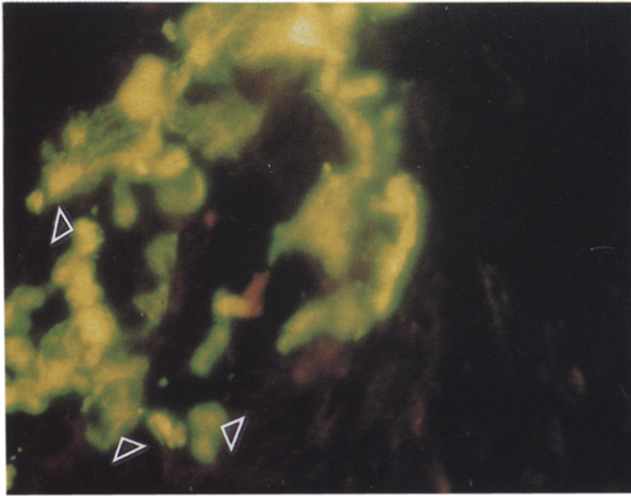


FIGURE 1. Fixed sections from NPC 54 were reacted with monoclonal antisera as described in the Materials and Methods section. After excitation with UV light, the Evans blue counterstain shows up as red, whereas the specific FITC fluorescence shows up as green/yellow. Monoclonal antibodies: top left, LP34; top right, CS1-4; bottom, PE2. (Magnification $\times 514$.)

Antibodies

The monoclonal mouse anti-human cytokeratin antibody LP34 (Dakopatts, Copenhagen, Denmark) was obtained as cell culture supernate and was used at a dilution of 1:50. The mouse monoclonal anti-LMP antibody pool CS1-4²⁴ and the mouse monoclonal anti-EBNA2 antibody PE2²⁵ were both obtained as cell culture supernates from Drs M. Rowe and L. S. Young, University of Birmingham (Birmingham, UK) and were used at a dilution of 1:2.

Immunofluorescence

All incubations were performed with a volume of 20 μ L per section and all dilutions were made using phosphate-buffered saline (PBS) containing 0.05% Tween-20 (Sigma, St Louis, MO) and 5% normal rabbit serum (Dakopatts; PBST-NRS). Slides were washed three times (5 minutes each time) between incubations in PBS containing 0.05% Tween-20. Tissue sections were first preincubated with PBST-NRS for 30 minutes. This and all subsequent incubations were performed at 37°C using a humidified box. Excess liquid was removed from the sides and diluted monoclonal antibody was added. The slides were then incubated for 1 hour before being washed.

Biotinylated F(ab)₂ fragment of rabbit anti-mouse immunoglobulins (Dakopatts E413) diluted 1:200 was then added and the slides were incubated for 30 minutes. After washing, the slides were then incubated (30 minutes) with a 1:200 di-

lution of FITC-conjugated streptavidin (Dakopatts F422). After washing, the sections were counterstained by incubation for 10 to 30 seconds with an aqueous solution containing 0.1% Evans blue. Excess stain was then washed off and the sections were mounted in PBS containing 50% glycerol and 2.5% 1,4-diazabicyclo[2,2,2]octane (Sigma), which prevents fading. Fluorescence was produced and analyzed using a Leitz ortholux UV microscope. Photographs were taken using Ektachrome 160 color slide film (Kodak, Kirkby, UK).

RESULTS

Nine snap-frozen biopsy specimens (identified as NPCs 13, 15, 16, 18, 23, 35, 40, 54, and 55) were chosen at random from a collection of histologically diagnosed undifferentiated NPCs. Serial sections were cut from these specimens and were probed individually with monoclonal antibodies. The sections were counterstained with Evans blue, which stains the cytoplasm of all cells and appears red when examined with a UV microscope. The tumor (epithelial) tissue present in the biopsy specimen was identified by using the monoclonal antibody LP34. This antibody reacts with a number of cytokeratins and can distinguish tumor cells that are of epithelial origin.^{26,27} When stained with LP34, large

areas of epithelial tumor tissue were observed in all three biopsy specimens. An example of this is shown in Fig 1, top left, in which a nest of tumor cells in NPC 54 can be seen encapsulated by stromal cells. Due to the intensity of the fluorescence using LP34, Fig 1, top left, was underexposed relative to the other panels; hence, the red counterstain does not show up as well.

Serial sections obtained from the biopsy specimens were then probed with monoclonal antibodies that are specific for the EBV latent proteins EBNA2 and LMP. In our previous experience both the anti-EBNA2 monoclonal antibody PE2 and the anti-LMP monoclonal antibody pool CS1-4 have been shown to react in a specific fashion with fixed B cells containing EBV or with epithelial cells infected with recombinant vaccinia viruses expressing the relevant antigens.^{28,29} In studies conducted by other investigators both reagents have reacted in a specific fashion with the respective antigens in tumor sections.²⁵ When the tissue sections were probed with PE2, none of the biopsy specimens displayed any staining, showing that EBNA2 was not expressed in these tumors. Figure 1, bottom, which represents the same area of NPC 54 as shown in Fig 1, top left, is an example of this. When the sections were probed with CS1-4, seven biopsy specimens showed specific staining, whereas the two NPCs (40 and 55) were entirely negative. At low power, it could be seen that areas of LMP expression in NPC 54 were identical to the areas where LP34 staining had been observed in the serial section. At high power, as can be seen in Fig 1, top right, staining of cells with CS1-4 matched the LP34 staining of the nest of tumor cells seen in Fig 1, top left. The three arrows indicate individual cells that are present in both serial sections and that stain with both LP34 and CS1-4. These results indicate that LMP was expressed in the tumor cells present in the NPC 54 biopsy specimen. Figure 1, top right, also shows that LMP has a distinctive pattern of staining. Thus, the protein is localized to the plasma membrane of the tumor cells in discrete patches and caps. This pattern of staining is similar to that displayed by LMP in B cells that have been immortalized by EBV *in vitro*²⁴ and by epithelial cells that have been infected with a vaccinia virus expressing LMP.^{28,29}

DISCUSSION

The association between EBV and NPC has been known for some time. Previous studies of EBV antigen expression in NPC showed that EBNA was expressed by the epithelial tumor cells and not by the lymphocytes present in these biopsy specimens.^{10,11} To demonstrate this, these biopsy specimens were disaggregated before analysis. With the realization that EBNA was a complex of antigens and that some of these were associated with cellular transformation came further analyses of EBV antigen expression in NPC. Two published reports analyze protein expression by Western blot analysis.^{21,22} Some of the lymphocytes that infiltrate NPCs, albeit a minority, are B cells and could potentially contain EBV.³⁰ The aim of the study presented here was to confirm earlier observations that LMP, but not EBNA2,

was expressed in NPC, to show that this expression was localized to the tumor cells within the biopsy specimen, and, hence, to assess whether LMP could have a role in the development of the tumor.

Our results show that LMP was expressed in the tumor cells of seven of nine biopsy specimens analyzed. This result is in concordance with the Western blot analysis results obtained by Fahraeus et al²¹ and Young et al,²² who found that LMP was found in only a proportion (70%) of the biopsy specimens tested. This suggests that either there are subsets of NPC that cannot be distinguished by using conventional histopathologic techniques or that LMP is expressed at different stages during tumor development. The only other EBV antigen found to be expressed in NPC is EBNA1, which has been shown to be present in all biopsy specimens.^{21,22} This agrees with our finding that EBNA2 was not expressed in any of the NPCs tested.

It is not clear what precise role EBV plays in the development of NPC. The virus does, however, have an extremely close association with tumor tissue, and rising antibody titers to EBV antigens are of diagnostic and prognostic significance,³¹ both of which argue for a causal rather than a casual role in the tumor. When EBV immortalizes B cells *in vitro*, a restricted set of latent genes is expressed. In NPC the expression of genes also is restricted, but in a different fashion. This indicates a different association of the virus with the epithelial tumor cell as compared with that with immortalized B cells. Little is known about the functions of EBV latent genes. By binding to the origin of replication (*Ori-P*), EBNA1 has been shown to be essential for virus maintenance as an episome within cells.³² Thus, the function of EBNA1 within tumor cells probably is to maintain the virus. Expression of LMP in rodent fibroblast cells has been shown to drive these cells toward a more transformed phenotype,¹⁷⁻²⁰ and expression of LMP has been shown to block the terminal differentiation of human keratinocyte lines *in vitro*.³³ Thus, it can be easily envisaged how expression of LMP by EBV in oropharyngeal epithelia could have a role in tumorigenesis. The results presented here clearly show that only a proportion of NPCs express LMP. It is conceivable, therefore, that LMP may be required only at certain stages in the development of NPC. In future studies it would be of interest to determine whether LMP expression correlates with tumor progression and, hence, to further assess the role of EBV in this malignancy.

Acknowledgment. The authors would like to thank Dr Jin-Quan Jiang for providing the NPC biopsy specimens and Drs M. Rowe and L. S. Young for the kind gift of the monoclonal reagents CS1-4 and PE2. The authors also would like to thank Drs Cliona Rooney, Clare Sample, and John Sixbey for reviewing the manuscript.

REFERENCES

1. Henle W, Henle G: Seroepidemiology of the virus, in Epstein MA, Achong BG (eds): *The Epstein-Barr Virus*. Berlin, Germany, Springer-Verlag, 1979, pp 67-86

2. Fingerroth JD, Weiss JJ, Tedder TF, et al: Epstein-Barr virus receptor of human B lymphocytes is the C3d receptor CR2. *Proc Natl Acad Sci USA* 81:4510-4514, 1984
3. Sixbey JW, Nedrud JG, Raab-Traub N, et al: Epstein-Barr virus replication in oropharyngeal epithelial cells. *N Engl J Med* 310:1225-1230, 1984
4. Cleary ML, Dorfman RF, Sklar J: Failure in immunological control of the virus infection: Post-transplant lymphomas, in Epstein MA, Achong BG (eds): *The Epstein-Barr Virus: Recent Advances*. London, UK, Heinemann, 1986, pp 163-181
5. Epstein MA, Achong BG, Barr YM: Virus particles in cultured lymphoblasts from Burkitt's lymphoma. *Lancet* 1:702-703, 1964
6. Simons MJ, Shanmugaratnam K (eds): *The Biology of Nasopharyngeal Carcinoma*. Technical Report Series, vol 72. Geneva, Switzerland, UICC, 1982
7. Zur Hausen H, Schulte-Holthausen H, Klein G, et al: EBV DNA in biopsies of Burkitt tumours and anaplastic carcinomas of the nasopharynx. *Nature* 228:1056-1059, 1970
8. Nonoyama M, Huang CH, Pagano JS, et al: DNA of Epstein-Barr virus detected in tissue of Burkitt's lymphoma and nasopharyngeal carcinoma. *Proc Natl Acad Sci USA* 70:3265-3268, 1973
9. Wolf H, Zur Hausen H, Becker V: Epstein-Barr virus genomes in epithelial nasopharyngeal carcinoma cells. *Nature New Biol* 244:245-247, 1973
10. Klein G, Giovanella BC, Lindahl T, et al: Direct evidence for the presence of Epstein-Barr virus DNA and nuclear antigen in malignant epithelial cells from patients with poorly differentiated carcinoma of the nasopharynx. *Proc Natl Acad Sci USA* 71:4737-4741, 1974
11. Huang DP, Ho JH, Henle W, et al: Demonstration of Epstein-Barr virus-associated nuclear antigen in nasopharyngeal carcinoma cells from fresh biopsies. *Int J Cancer* 14:580-588, 1974
12. Dillner J, Kallin B: The Epstein-Barr virus proteins. *Adv Cancer Res* 50:95-158, 1988
13. Fennewald S, Van Santen U, Kieff E: Nucleotide sequence of an mRNA transcribed in latent growth-transforming virus infection indicates that it may encode a membrane protein. *J Virol* 51:411-419, 1984
14. Laux G, Perricaudet M, Farrell PJ: A spliced Epstein-Barr virus gene expressed in immortalised lymphocytes is created by circularisation of the linear viral genome. *EMBO J* 7:769-774, 1988
15. Dambaugh T, Wang F, Hennessy K, et al: Expression of the Epstein-Barr virus nuclear antigen 2 in rodent cells. *J Virol* 59:453-462, 1986
16. Hammerschmidt W, Sugden B: Genetic analysis of immortalising functions of Epstein-Barr virus in human B lymphocytes. *Nature* 340:393-397, 1989
17. Wang D, Liebowitz D, Kieff E: An EBV membrane protein expressed in immortalized lymphocytes transforms established rodent cells. *Cell* 43:831-840, 1985
18. Baichwal VR, Sugden B: Transformation of Balb 3T3 cells by the BNLF-1 gene of Epstein-Barr virus. *Oncogene* 2:461-467, 1988
19. Wang D, Liebowitz D, Kieff E: The truncated form of the Epstein-Barr virus latent membrane protein expressed in virus replication does not transform rodent fibroblasts. *J Virol* 62:2337-2346, 1988
20. Baichwal VR, Sugden B: The multiple membrane-spanning segments of the BNLF-1 oncogene from Epstein-Barr virus are required for transformation. *Oncogene* 4:67-74, 1989
21. Fahraeus R, Fu HL, Ernberg I, et al: Expression of Epstein-Barr virus-encoded proteins in nasopharyngeal carcinoma. *Int J Cancer* 42:329-338, 1988
22. Young LS, Dawson CW, Clark D, et al: Epstein-Barr virus gene expression in nasopharyngeal carcinoma. *J Gen Virol* 69:1051-1065, 1988
23. Jondal M, Klein G: Classification of lymphocytes in nasopharyngeal carcinoma (NPC) biopsies. *Biomedicine* 23:163-165, 1975
24. Rowe M, Evans HS, Young LS, et al: Monoclonal antibodies to the latent membrane protein of Epstein-Barr virus reveal heterogeneity of the protein and inducible expression in virus-transformed cells. *J Gen Virol* 68:1575-1586, 1987
25. Young LS, Alfieri C, Hennessy K, et al: Expression of Epstein-Barr virus transformation-associated genes in tissues of patients with EBV lymphoproliferative disease. *N Engl J Med* 321:1080-1085, 1989
26. Gatter KC, Abdulaziz Z, Beverley P, et al: Use of monoclonal antibodies for the histopathological diagnosis of human malignancy. *J Clin Pathol* 35:1252-1267, 1982
27. Gatter KC, Falini B, Mason DY: The use of monoclonal antibodies in histopathological diagnosis, in Anthony PP, McSween NM (eds): *Recent Advances in Histopathology*, vol 12. London, UK, Churchill Livingstone, 1984, pp 35-67
28. Stewart JP, Hampson IN, Heinrich H-W, et al: Enhanced expression of the Epstein-Barr virus latent membrane protein by a recombinant vaccinia virus. *J Gen Virol* 70:1231-1237, 1989
29. Stewart JP: Recombinant vaccinia viruses expressing EBV latent proteins: Construction and applications. PhD thesis, University of Manchester, Manchester, UK, 1990
30. Thomas JA, Iliescu V, Crawford DH, et al: Expression of HLA-DR antigens in nasopharyngeal carcinoma: An immunohistochemical analysis of the tumour cells and infiltrating lymphocytes. *Int J Cancer* 33:813-819, 1984
31. Zeng Y: Seroepidemiological studies on nasopharyngeal carcinoma in China. *Adv Cancer Res* 44:121-138, 1985
32. Yates JL, Warren N, Sugden B: Stable replication of plasmids derived from Epstein-Barr virus in various mammalian cells. *Nature* 313:812-815, 1985
33. Dawson CW, Rickinson AB, Young LS: Epstein-Barr virus latent membrane protein inhibits human epithelial cell differentiation. *Nature* 344:777-780, 1990